

PRIMARY WOUND CARE AND EXTERNAL SKELETAL FIXATION IN SURGICAL TREATMENT OF OPEN TIBIAL FRACTURES

Ivana Golubović¹, Predrag Stojiljković^{1,2}, Ivan Golubović², Zoran Radovanović^{1,4},
Milan Radojković^{1,5}, Aleksandar Mitić¹, Zoran Baščarević³, Katarina Kutlešić²,
Andrija Krstić¹, Stevo Najman¹, Zoran Golubović^{1,2}

Open tibial fractures are the most severe orthopaedic injuries. The lower leg is often injured due to its position in the locomotor system. The injuries of the lower leg skin and soft tissues, bone comminution and threatening infections make the treatment of these fractures particularly complex. The management of open tibial fractures is potentially associated with numerous complications.

The data on treatment outcomes of 36 patients operatively treated for the open tibial fractures in Clinic for Orthopaedic surgery and traumatology, Clinical Center Nis in Serbia during the period from January 1, 2012 to June 31, 2014 were retrospectively analyzed and compared. In all the patients, after thorough wound rinsing, removal of the foreign bodies, debridement and delayed wound closure, fractured bone segments were repositioned and stabilized using external fixator.

In 28 (77.78%) patients fractures healed without major complications, while in 8 (22.22%) major complications occurred, including tibial osteomyelitis in 3 (8.33%) and fracture malunion in 5 (13.88%) patients.

Primary wound care, external fixation, antibiotic and antitetanus prophylaxis are crucial in treatment of open tibial fracture.

Acta Medica Medianae 2018;57(4):22-28.

Key words: Open tibial fractures, primary wound care, external skeletal fixation

¹University of Niš, Faculty of Medicine, Serbia

²Clinic for Orthopaedic Surgery and Traumatology, Clinical center Niš, Serbia

³Institute for Orthopaedic Surgery 'Banjica', Belgrade, Serbia

⁴Radiology Center, Clinical Center Niš, Niš, Serbia

⁵Surgery Clinic, Clinical Center Niš, Niš, Serbia

Contact: Zoran Golubović

Gutenbergova 37, 18000 Niš, Serbia

E-mail: doktorzorangolubovic@gmail.com

Introduction

Open tibial fractures are the most severe orthopaedic injuries. The lower leg is often injured due to its position in the locomotor system. Tibial diaphysis fractures are the most common of all long bone diaphyseal fractures in 40%, while the open tibial fractures are the most common open bone fractures (1). Open tibial fractures are closed in 77 % and open in 33% (2). Open tibial fracture occurs in approximately two per 10 000 persons per year in the developed country (3). Open lower leg fractures most commonly occur in traffic accidents and during agricultural and sport activities (1). The injuries of

the lower leg skin and soft tissues, bone comminution and threatening infections make the treatment of these fractures particularly complex. The treatment includes thorough wound rinsing, removal of foreign bodies, debridement, bone segments reposition, external fixation or internal fixation, antibiotic therapy and antitetanus prophylaxis (4).

The management of open lower leg fractures is potentially associated with numerous complications including: soft tissue infection, osteomyelitis, fracture malunion/nonunion and the loss of the extremity (5). The management success depends on both the severity of injury, patient's general condition and comorbidities and treatment modality applied.

The aim of the study

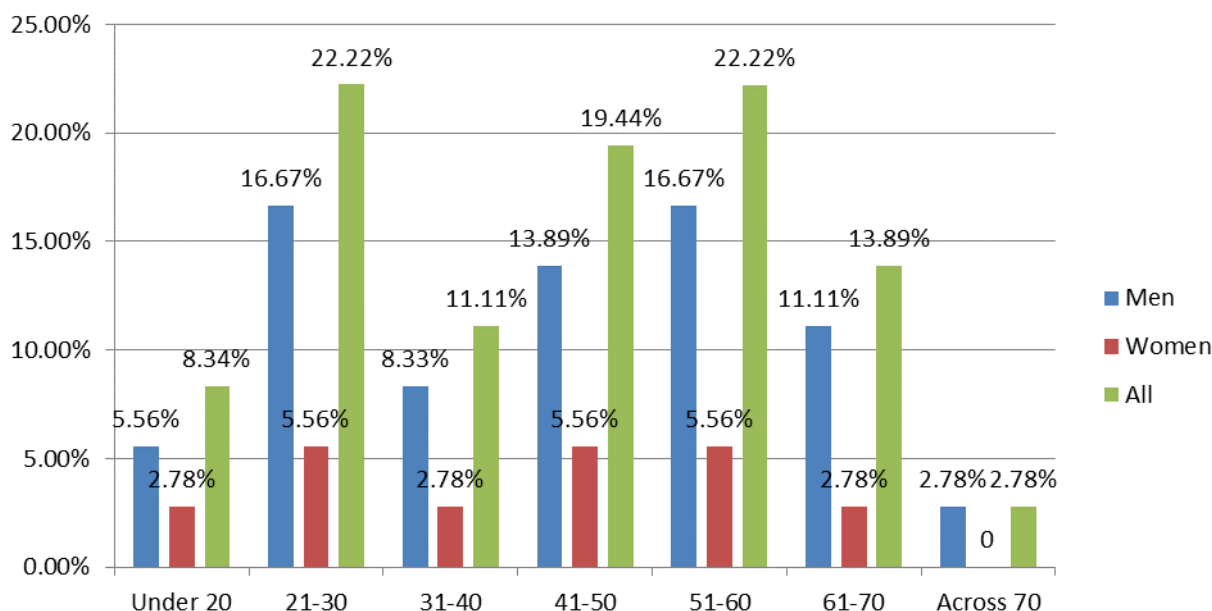
The aim of our study was to present the results of the open lower leg fracture treatment with primary wound closure, external fixation, antibiotic and antitetanus prophylaxis.

Materials and methods

The data on treatment outcomes of 36 patients operatively treated for the open tibial fractures

in Clinic for Orthopaedic surgery and traumatology, Clinical Center Nis in Serbia during the period from January 1, 2012 to June 31, 2014 were retrospectively analyzed and compared.

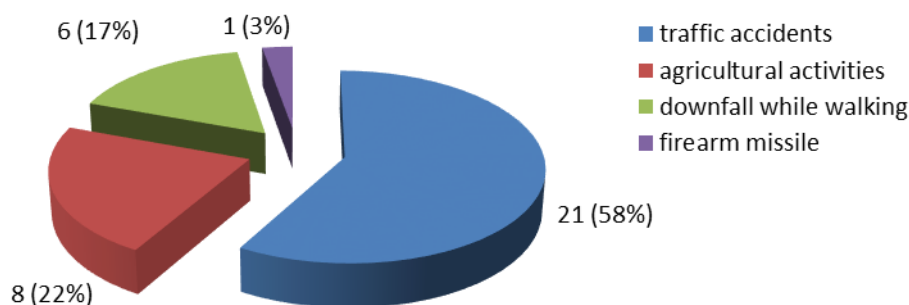
There were 27 (75%) men and 9 (25%) women, most of which being in the third 8 (22.22%), fifth 7 (19.44%) and sixth 8 (22.22%) decade of life (Graph 1).



Graph 1. Gender and age distribution of the patients

Most of the patients were injured in the traffic accidents 21 (58%), while 8 (22%) of them were injured during the agricultural activities. The downfall

while walking caused the injury in 6 (17%) patients and 1 (3%) was injured by a firearm missile (Graph 2).



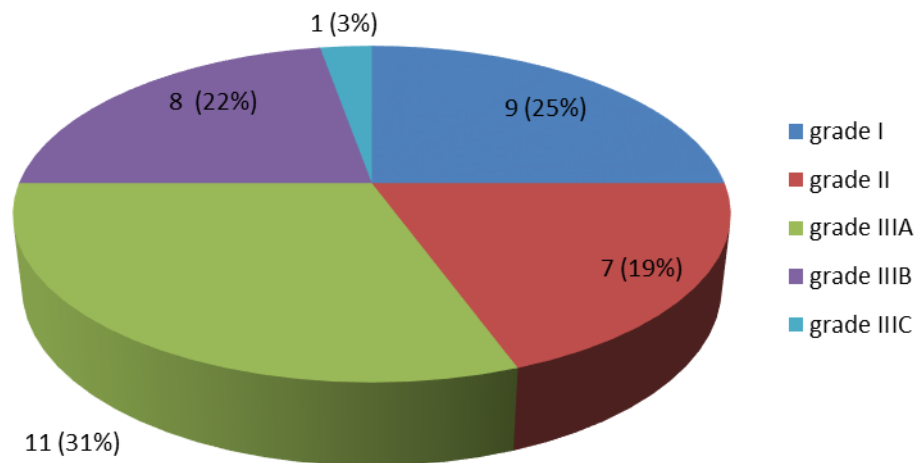
Graph 2. The mechanisms of injury

For the analysis we used the open fracture classification system established by Ramon Gustilo (6) according to which there were 9 (25%) patients with grade I, 7 (19%) with grade II, 11 (31%) with grade IIIA, 8 (22%) with grade IIIB and one (3%) with grade IIIC open lower leg fracture (Graph 3).

In all the patients, after thorough wound rinsing, removal of the foreign bodies, debridement and

delayed wound closure, fractured bone segments were repositioned and stabilized using Mitkovic external fixator.

Immediately upon admission, all patients were administered antimicrobial therapy that included the combination of a third-generation cephalosporin (ceftriaxone, 2gr/24h) and semi-synthetic aminoglycoside (amikacin, 1gr/24h).



Graph 3. The severity of injuries of our patients according to the Gustilo open fracture classification

Extremely contaminated wounds, for example with soil, with increased risk of clostridial infection and gas gangrene, required the administration of additional antibiotic (penicillin G sodium, 4 to 6 million units/day or clindamycin). All patients received anti-tetanus prophylaxis according to the protocol.

Results

In 28 (77.78%) patients fractures healed without major complications (Figure 1), while in 8 (22.22%) major complications occurred including tibial osteomyelitis in 3 (8.33%) and fracture malunion in 5 (13.88%) patients (Graph 4). Minor complications such as soft tissue infection, surrounding the pins of external fixator and soft tissue infection were detected in 6 (16.67%) and 4 (11.11%) patients, respectively.

Infection of the soft tissue surrounding the pins and soft tissue infection were successfully treated with thorough daily debridement and wound care

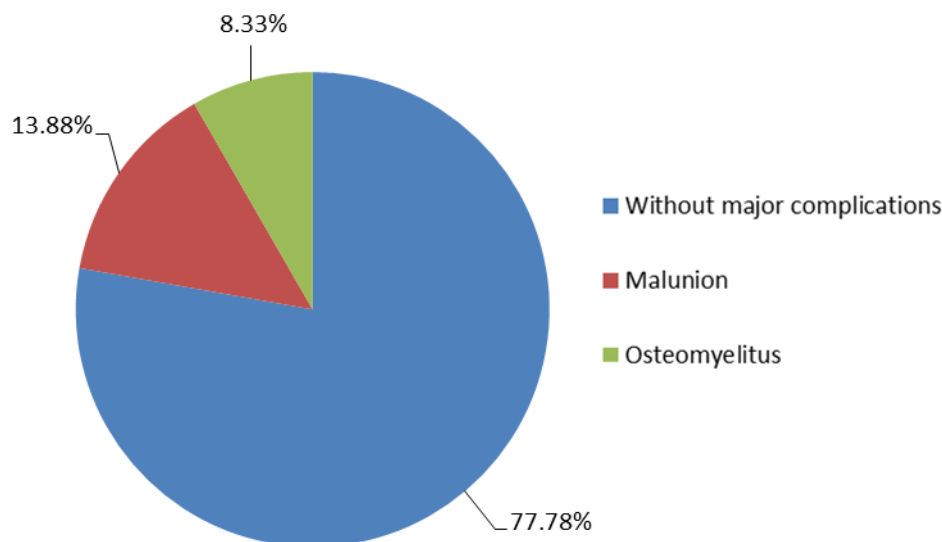
and antimicrobial medication according to the anti-biogram results. Tibial osteomyelitis developed in one patient with grade IIIA and 2 patients with grade IIIB open fractures. Fracture malunion and pseudoarthrosis occurred in one patient with grade II, 2 patients with grade IIIA and 2 patients with grade IIIB fractures. In 2 (5.56%) patients primary bone comminution caused nonunion, while in 3 (8.33%) patients open fractures resulted in tibial hypertrophic pseudoarthrosis.

Discussion

Open lower leg fractures most commonly occur in traffic accidents, with the direct mechanism of injury. The indirect mechanism of injury implies the rupture of lower leg soft tissue and skin from the inside with sharp segment(s) of fractured bone(s) resulting in open fracture. Indirect mechanism often causes less severe injuries compared to the direct mechanism (1).

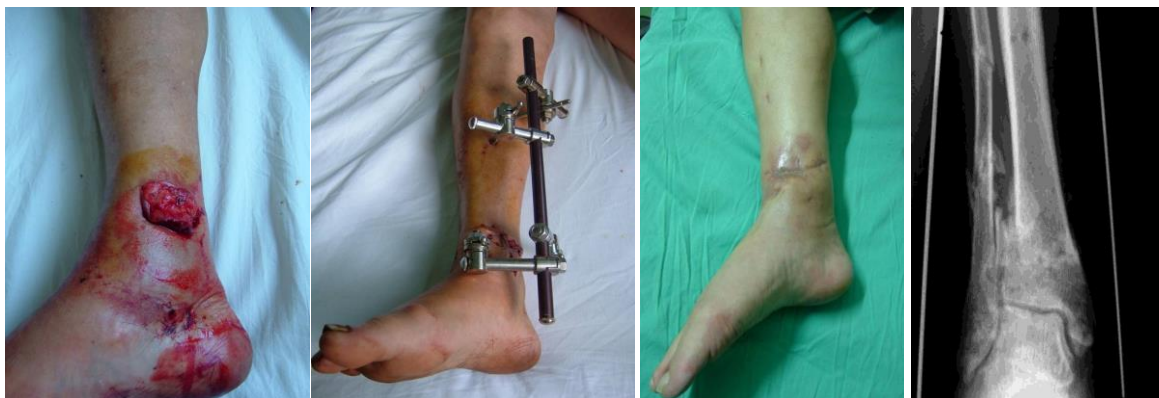

Figure 1. Open tibial fracture treated with external fixator Mitkovic



Graph 4. Open tibial fracture treatment results

All open fractures are considered primarily contaminated. Among numerous classifications the most commonly used is the one proposed by Ramon Gustilo based on the strength of the force that caused the lower leg bone fracture and soft tissue damage (6).

Lower leg open fractures require urgent surgical treatment in case of satisfactory general condition of the patient. The "6-hour rule", long-accepted guideline for dealing with open fractures, stating that, to prevent infection, open fractures should be fully managed within a 6-hour time frame, should be applied as its relevance is supported by the evidence provided by Kindsfater and Jonassen (7) and Kreder and Armstrong (8) in 1995.

Early parenteral antibiotic administration is associated with the infection incidence decrease and should be applied immediately upon admission. Antibiotic treatment is to be administered during 48 to 76 hours in patients with grade I and II and up to 120 hours in patients with grade III open fractures (9).

Primary wound care is essential for the prevention of osteomyelitis, gas gangrene and tetanus. Before detailed debridement, thorough wound rinsing using saline and hydrogen and removal of foreign bodies, including the parts of soil and clothing and bone fragments, should be done. Sometimes, more than 10L of liquid are required for quality wound rinsing. It includes the removal of damaged skin, subcutaneous fat, fascia, and muscles, as well as removal of small periosteum bone fragments. Necrotic muscle tissue is a good host for both anaerobic and aerobic bacteria. When assessing the muscle vitality, its colour, consistency, bleeding and contractility should be taken into consideration (1).

Widely accepted surgical treatment of the Gustilo-Anderson types IIIB and IIIC open fractures these days is a routine treatment involving the use of external fixation (10, 11).

External fixation is a standard method of all lower leg fracture stabilization. It provides good bio-mechanical conditions for fracture healing, allows good approach for wound care and it does not interfere with the knee and ankle movements. Problems associated with this fixation method include frequent soft tissue and bone infections around the pins when the fixator is applied longer than 6 months and higher incidence of fracture malunion and nonunion (12).

Satisfactory clinical function has been achieved with external fixation at the 89% of the patients with open tibial fractures Grade III with 93% of the fractures healing well and as expected, which was noted in a study case conducted by Edward in 1988 (13).

Intramedullary nailing in the therapy of Grade IIIB and IIIC fractures was leading to infection in 20.3% of the cases and therefore was proclaimed the risky treatment by Yokoyama K (14).

Moreover the conclusion is that using secondary nailing after delayed primary one or primary external fixator is increases the risk of infection (15).

Fracture management with intramedullary nailing and external fixation was compared through several clinical trials; both ways were applied to treat the open tibial shaft fractures. The selection of the treatment depended both on surgical experience of the doctor as well as on patient presentation. Advantages of external fixation treatment are shorter time and its suitability in polytrauma patients, but on the other hand it has many disadvantages such as high incidence of complications like refracture, nonunion or delayed union and not always being well tolerated by the patients. While on the other side, intramedullary nailing includes less time for healing, earlier load-bearing and extremely low risk of complications (15-17).

Osteosynthesis with plate should be avoided in treatment of open tibial fractures due to high risk of infection (18).

Open fracture wound should not be primary closed, but left open and closed using secondary sutures or some of the plastic surgery techniques (depending on the severity of the soft tissue damage/defect such as fasciocutaneous flap, microvascular transplantation etc.) when certain that no infection occurred (1). Closing the wound as early as possible, according to contemporary orthopaedic principles, requires previous thorough debridement and absence of contamination. Caudle and Stern reported that early aggressive soft tissue reconstruction during the first 7 days after the injury, in order to cover the fractured bone segments in patients with grade III open fractures, significantly reduces the risk of infection, fracture malunion/nonunion and amputation (19).

Conclusion

Primary wound care, external fixation, antibiotic and antitetanus prophylaxis, delayed wound closure are crucial in treatment of open tibial fracture. Most common complications of open tibial fracture are deep bone infection – osteomyelitis and fracture malunion or nonunion.

Acknowledgment

This work is part of the project "Virtual human osteoarticular system and its application in preclinical and clinical practise" (No. III 41017), supported by was funded by the Ministry of Education, Science and Technological Development of Serbia.

References

1. Golubović Z, Stojiljković P, Mačukanović-Golubović L, Milić D, Milenković S, Kadija M, et al. External fixation in the treatment of open tibial shaft fractures. *Vojnosanitetski Pregled* 2008; 65(5):343-7. [\[CrossRef\]](#) [\[PubMed\]](#)
2. Court-Brown CM, McBirnie J. The epidemiology of tibial fractures. *J Bone Joint Surg* 1995; 77B:417-21. [\[CrossRef\]](#) [\[PubMed\]](#)
3. Court-Brown CM, Bugler KE, Clement ND, Duckworth AD, McQueen MM. The epidemiology of open fractures in adults: a 15-year review. *Injury* 2012; 43:891-7. [\[CrossRef\]](#) [\[PubMed\]](#)
4. Cross WW, Swiontkowski MF. Treatment principles in the management of open fractures. *Indian J Orthop* 2008; 42(4):377-86. [\[CrossRef\]](#) [\[PubMed\]](#)
5. Kohlprath R, Assal M, Ucakay I, Holzer N, Hoffmeier P, Suva D. Open fractures of the tibia in the adult: surgical treatment and complications. *Rev Med Suisse* 2011; 7(322):2482-4. [\[PubMed\]](#)
6. Gustilo RB, Mendoza RM, Williams DN. Problems in the management of type III (severe) open fractures. A new classification of type III open fractures. *J Trauma* 1984; 24:742-6. [\[CrossRef\]](#) [\[PubMed\]](#)
7. Kindsfater K, Jonassen EA. Osteomyelitis in grade II and III open tibia fractures with late debridement. *J Orthop Trauma* 1995; 9(2):121-7. [\[CrossRef\]](#) [\[PubMed\]](#)
8. Kreder HJ, Armstrong P. A review of open tibia fractures in children. *J Pediatr Orthop* 1995; 15(4): 482-8. [\[CrossRef\]](#) [\[PubMed\]](#)
9. Golubovic I, Vukasinovic Z, Stojiljkovic P, Golubovic Z, Stamenic S, Najman S. Open segmental fractures of the tibia treated by external fixation. *Srp Arh Celok Lek* 2012; 140(11-12):732-7. [\[CrossRef\]](#) [\[PubMed\]](#)
10. McKee MD, Yoo DJ, Zdero R, Dupere M, Wild L, Schemitsch EH, et al. Combined single-stage osseous and soft tissue reconstruction of the tibia with the

- Ilizarov method and tissue transfer. *J Orthop Trauma* 2008; 22(3):183-9. [\[CrossRef\]](#) [\[PubMed\]](#)
11. Kataria H, Sharma N, Kanojia RK. Small wire external fixation for high-energy tibial plateau fractures. *J Orthop Surg* 2007; 15(2):137-43. [\[CrossRef\]](#) [\[PubMed\]](#)
 12. Mitković M, Bumbaširević M, Golubović Z, Mičić I, Mladenović D, Milenković S, et al. New concept in external fixation. *Acta Chir Iugosl* 2005; 52(2): 107-11. [\[CrossRef\]](#) [\[PubMed\]](#)
 13. Edwards CC, Simmons SC, Browner BD, Weigel MC. Severe open tibial fractures. Results treating 202 injuries with external fixation. *Clin Orthop Relat Res* 1988; 230:98-115. [\[PubMed\]](#)
 14. Yokoyama K, Itoman M, Uchino M, Fukushima K, Nitta H, Kojima Y. Immediate versus delayed intramedullary nailing for open fractures of the tibial shaft: a multivariate analysis of factors affecting deep infection and fracture healing. *Indian J Orthop* 2008; 42(4): 410-9. [\[CrossRef\]](#) [\[PubMed\]](#)
 15. Blachut PA, Meek RN, O'Brien PJ. External fixation and delayed intramedullary nailing of open fractures of the tibial shaft. *J Bone Joint Surg Am* 1990; 72(5):729-35. [\[CrossRef\]](#) [\[PubMed\]](#)
 16. Koval KJ, Clapper MF, Brumback RJ, Stribling Ellison P, Poka A, Bathon H, et al. Complication of reamed intramedullary nailing of the tibia. *J Orthop Trauma* 1991; 5:184-9. [\[CrossRef\]](#) [\[PubMed\]](#)
 17. Court-Brown CM, Keating JF, McQueen MM. Infection after intramedullary nailing of the tibia. *J Bone J Surg* 1992; 74(B):770-4. [\[PubMed\]](#)
 18. Melvin JS, Domrizekabrski DG, Torbert JT, Kovach SJ, Esterhai JL, Mehta S. Open tibial shaft fractures: II. Definitive management and limb salvage. *J Am Acad Orthop Surg* 2010; 18:108-17. [\[CrossRef\]](#) [\[PubMed\]](#)
 19. Caudle RJ, Stern PJ. Severe open fractures of the tibia. *J Bone Joint Surg Am* 1987; 69(6):801-7. [\[CrossRef\]](#) [\[PubMed\]](#)

Originalni rad

UDC: 616.718.5-001.5-089.23
doi:10.5633/amm.2018.0403**PRIMARNA OBRADA RANE I SPOLJNA SKELETNA FIKSACIJA
U LEČENJU OTVORENIH PRELOMA TIBIJE**

*Ivana Golubović¹, Predrag Stojiljković^{1,2}, Ivan Golubović², Zoran Radovanović^{1,4},
Milan Radojković^{1,5}, Aleksandar Mitić¹, Zoran Baščarević³, Katarina Kutlešić²,
Andrija Krstić¹, Stevo Najman¹, Zoran Golubović^{1,2}*

¹Univerzitet u Nišu, Medicinski fakultet, Srbija

²Klinika za ortopedsku hirurgiju i traumatologiju, Klinički centar u Nišu, Srbija

³Specijalna ortopedska bolnica Banjica, Beograd, Srbija

⁴Centar za radiologiju, Klinički centar Niš, Niš, Srbija

⁵Klinika za digestivnu hirurgiju, Klinički centar Niš, Niš, Srbija

Kontakt: Zoran Golubović
Gutenbergova 37, 18000 Niš, Srbija
E-mail: doktorzorangolubovic@gmail.com

Otvoreni prelomi tibije spadaju u najteže ortopedске povrede. Zbog svog položaja u lokomotornom sistemu, potkolenica se često povređuje. Povrede kože i mekog tkiva potkolenice, kominukacija kosti i prateće infekcije čine lečenje ovih preloma naročito složenim.

Lečenje otvorenih preloma potkolenice je potencijalno povezano sa brojnim komplikacijama. U radu se prikazuju rezultati operativnog lečenja 36 pacijenata sa otvorenim prelomom potkolenice, koji su lečeni u Klinici za ortopediju i traumatologiju Kliničkog centra u Nišu u periodu od 1. januara 2012. do 31. juna 2014. godine. Kod svih pacijenata, nakon primarne obrade rane, odstranjivanja stranih tela, debridmana i odloženog zatvaranja rane, polomljeni koštani fragmenti su reponirani i stabilizovani korišćenjem spoljašnjeg skeletnog fiksatora.

Kod 28 pacijenata (77,78%) prelom je zarastao bez većih komplikacija, dok je kod 8 (22,22%) pacijenata došlo do većih komplikacija, uključujući osteomijelitis tibije kod tri (8,33%) i nezarastanje preloma kod 5 (13,88%) pacijenata.

Primarna obrada rane, spoljna skeletna fiksacija, antibiotska i antitetanusna profilaksa su ključni u lečenju otvorenih preloma tibije.

Acta Medica Medianae 2018;57(4):22-28.

Ključne reči: otvoreni prelomi potkolenice, primarna obrada rane, spoljna skeletna fiksacija